Hong Kong Continence Society 香港理遺學會

Issue 30, Jun 2014 Newsletter

# Application of three-dimensional high resolution anorectal manometry in children

By Dr. Paula MY Tang, Associate Consultant, Department of Surgery, Queen Elizabeth Hospital

## Background

Defecation is a complex process involving rectal compliance, recto-anal sensation, normal colonic motility and coordinated muscular contractions. In a paediatric surgical or gastroenterology clinic, we commonly see children with constipation and fecal soiling problems. Most of these children have idiopathic causes. However, children with congenital colorectal anomalies after surgery can have continence problems. Hirschsprung's disease (HD) and anorectal malformation (Mal) can have post-operative defecation disorders. As the causes of constipation and fecal incontinence are often multifactorial, the assessment and management can be complicated.

While other modalities like magnetic resonance imaging (MRI) pelvis and endorectal ultrasound may provide useful information on the anatomy of the anal sphincter, they often require sedation and are usually poorly tolerated in children. The use of anorectal manometry (ARM) in the objective evaluation of anorectal neuromuscular function in adults has been well established. The internal and external anal sphincter pressure, rectal sensation and presence of recto-anal reflex can be measured by ARM.

There are increasing reports of ARM application on paediatric population. In conventional ARM, a trans-anal water-perfused multi-channel catheter is inserted to rectum. The channels of catheter are connected to a manometric device subsequently to the computer with pre-installed software for recording and analysis of the manometric parameters. The patient is positioned left laterally, usually accompanied by the parent or caretaker. Toys and sweets are often useful to help the patient to remain calm and cooperative during the study. Serial measurements of resting, squeeze and push pressures at different levels of anorectal region are measured. The catheter is manually withdrawn by a pull-through technique until it reached the anal sphincter region. Having said that, the conventional ARM may not be a "friendly" investigation for our young children, leading to inaccurate results and conclusions. With the evolution of technology, new generation of high resolution anorectal manometry (HRAM) has been released to the market and more recently there is three-dimensional (3D) HRAM system. The 3D HRAM catheter had four-quadrant channels at five consecutive levels that are 1cm apart. The individual channel measures the pressure of that particular quadrant of anorectal canal. After computer software reconstruction, the topographic appearance of rectum and anal sphincter anatomy can be regenerated. Moreover, 3D HRAM is a stationary technique so that we not need to shift the catheter in and out during the procedure, hence a more child-friendly test.

Website: www.hkcs.hk

There are very few literatures reviewing the use of 3D HRAM in children. The Boston group have reported the use of three dimensional high resolution anorectal manometry (HRAM) in 30 children with constipation defined by the Rome III criteria, and they have observed the radial and longitudinal asymmetry of the anal canal in these children. There is no published study on use of 3D HRAM on post-operative patients with congenital anorectal anomalies.

We believe an objective morphological and functional evaluation of the anorectal sphincter could improve the outcome of children with HD and Mal by facilitating the subsequent customized management plan.

## Patients & Methods

From June 2013, 14 neurologically healthy children with age 4 years or above, with surgical correction of HD and Mal in our hospital were recruited in this prospective study. Three patients with idiopathic constipation were also recruited as control group. Their demographic data and Rintala continence scores are shown in table 1. Patients with history of HD were further analyzed in their subgroups according to the surgical techniques employed (5 Soave endorectal pullthroughs, 2 myomectomies and 1 Duhamel operation).

With informed consent, all the recruited subjects were given bowel preparation prior to the study. The caretaker was allowed to accompany the child during the procedure to relieve anxiety. A surgeon is present during the entire procedure to conduct and analyze the pressure tracings. A single-use water perfused 24-channel catheter (figure 1) with four quadrant pressure channels at five 1cm spacings (Medical Measurement Systems B.V., MMS G-90520 The Netherlands) was used for manometry. All the patients remain awake and non-sedated for the measurement. The posterior marking on the probe was used to maintain the orientation in relation to the ventral and dorsal aspect of the anal canal. After identification of the high pressure zone (physiological anal sphincter) as shown by the sensors, the probe would then be held in place by taping it to the subject's buttock. The mean resting, squeeze, push anal sphincter pressure and recto-anal inhibitory reflex were measured. The orientation of the probe is checked regularly after each manoeuver to avoid rotation. The results were analyzed and displayed by the specific 3D HRAM software (figure 2).

*Contents:*

## Results

All the patients enrolled were able to complete the manometric study with no complications. In the HD group, the median mean resting pressure is 54mmmHg (range 31 – 70mmHg). In the Mal group, the median mean resting pressure is 56mmHg (range 22 – 80mmHg). In the control group, the median mean resting pressure is 71mmHg (range 21 – 87mmHg).

As there is no standardized definition of the symmetry of the radial pressure distribution of the anal canal in children, we arbitrarily define asymmetry of the anal sphincter as the intra-quadrants resting pressure difference > 25% at the level of the physiological sphincter. In the control group, all patients have symmetrical sphincter. In the subgroups within the HD group, all post Soave pullthrough patients have symmetrical sphincter, all post Duhamel pullthrough patients have asymmetrical sphincter. In the Mal group, all patients have asymmetrical sphincter.

## Discussion

There is a lack of normative data stratified for gender and age in the interpretation of the median resting pressure and anal sphincter symmetry in the postoperative patients of Hirschsprung's disease (HD) and anorectal malformation (Mal). According to literature search, this is the first study to-date using the three-dimensional high resolution anorectal manometry to evaluate the symmetry of the anal sphincter in postoperative patients. At present, due to the limited numbers of subjects recruited in this pilot study, we are unable to establish a normogram of the 3D HRAM values. Nonetheless, interestingly, we are able to observe significant asymmetries of the anal sphincter pressure in patients with history of surgical correction for Mal and patients with history of Duhamel operation for HD.

Based on the fact that the anal sphincter asymmetry are only found in patients who had a particular kind of surgical procedures, we postulated that the asymmetry could potentially be a result of the operations. Therefore, we inferred that the study of the pressure distribution in the anal canal would provide useful feedback information to the surgeons and might facilitate subsequent refinement of the surgical techniques.

The exact mechanism of fecal incontinence and constipation in children with HD and Mal are often poorly understood. The use of 3D HRAM would theatrically provide a dynamic and physiological mapping of the anal sphincter, and with further studies and correlation of the mapping with other investigation modalities, we believe it would become an increasingly common investigation modality in the management of children with defection disorders.

We believe that the different nature of the diseases and the different surgical techniques employed would potentially affect the degree of anal sphincter development, although in this pilot study we were not able to find a clinical correlation of the sphincter pressure status and the functional outcome (in terms of Rintala scores) of these patients.

The use of 3D HRAM in the assessment of postoperative anal sphincter condition is safe and child-friendly. It does not involve radiation, sedation or costly equipment. The results are also repeatable and non-operator dependent. There is good correlation of sphincter symmetry and the surgical techniques using the 3D HRAM, although further studies may be required to review the correlation of the functional symptoms and the 3D HRAM images.

We believe the use of 3D HRAM would facilitate the evaluation of surgical outcomes, improve communication between different specialties and guide the optimal bowel management plan of children with history of anorectal operations.

3D HRAM is a useful tool to standardize manometric evaluations and also to establish more control data of normative manometric parameters in children. These applications could help to refine diagnosis and management of patients with anorectal disorder.

## Legends of table & figures

*Table 1: The demographic data and Rintala continence scores of patients*

| Study groups | HD | Mal | Control |
|---|---|---|---|
| Gender | 4 M : 4 F | 2 M : 4 F | 3 M : 0 F |
| Age (years) | 8 (6 - 10) | 5 (4 - 9) | 14 (10 - 17) |
| Rintala score (/20) | 17.6 | 18.3 | 16 |

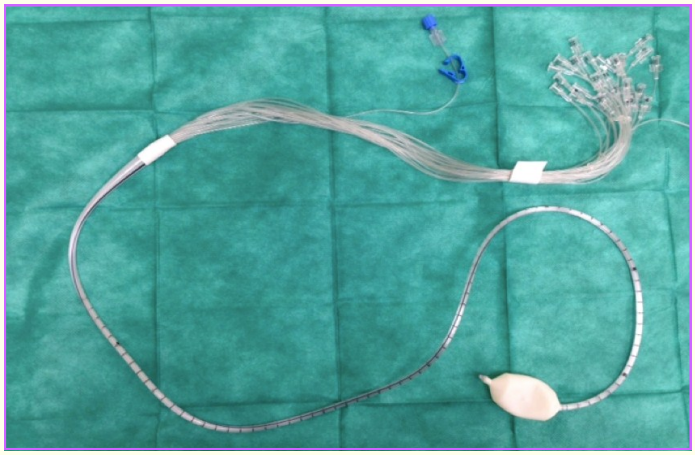

Fig 1: Three-dimensional high resolution anorectal manometry catheter

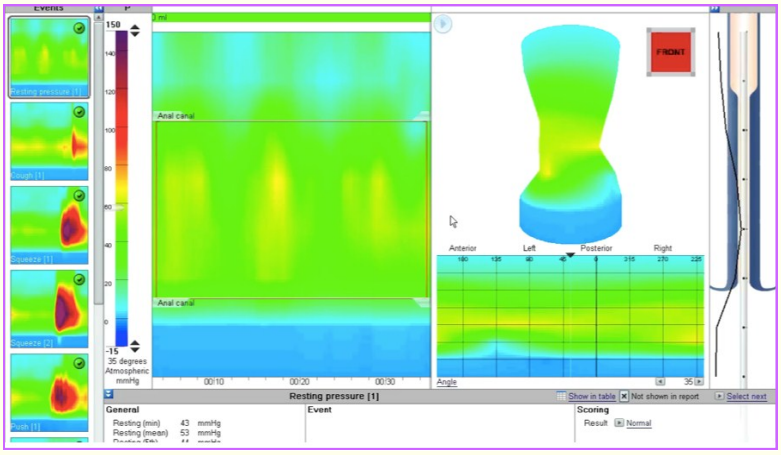


Fig 2: Topographic display & 3-D reconstruction of anal sphincter

# Announcement


## ICS 2014, Rio de Janeiro, Brazil

20th - 24th October 2014

**http://www.ics.org/2014**

## 2 nd Certificate Course in Assessment and Management of Incontinence 2014

**6 th September, 2014 ~ 22nd November, 2014**

*Organized by Hong Kong Continence Society Limited*

*Co-organizers: Hong Kong Association of Gerontology*

*Hong Kong Physiotherapy Association*

**Deadline for Registration: 24-8-2014 (Limited seats, First Come First Serve )**

**Enquiry: Hong Kong Association of Gerontology, Tel: 27755756**

**www.hkcs.hk**

# Basic Science and Principles of Surgical Management of Functional Bowel Disorders

*by Dr Luk Lai Yin, Specialist in General Surgery, Private Practice*

Fecal incontinence and functional constipation are two common types of functional bowel disorders. By understanding the basic anatomy and physiology of defecation, we will know more about the principles of surgical management of those diseases.

## Basic science of defecation

Rectum, acting as a transient reservoir for stool, is located at the pelvic region and measures around 15cm in length. Its high compliance, compared with colonic one, facilitates its main function to store feces temporarily. It is only sensitive to distension and the nerve supply is from autonomic nervous system (parasympathetic and pelvic plexus) (ie involuntary). Anal canal, joining the lower end of rectum, measures around 2-4cm and mainly acts as a plug to prevent stool leakage. Behind the mucosa and haemorrhoidal tissue of anal canal, there exist two concentric layers of sphincter muscles, namely the internal and external anal sphincters. The internal anal sphincter (IAS) constitutes the main role as gatekeeper as it contracts constantly with its though low muscle tone. It is supplied by both sympathetic and parasympathetic parts of autonomous nervous system. On the contrary, external anal sphincter (EAS) is supplied by somatic nervous system (ie voluntary). Its muscle tone is relatively strong but its contraction cannot last long.

Pelvic floor muscles (levator ani and coccygeus) are the base part of the pelvic cavity. They prevent the pelvic organs from being prolapsed. Puborectalis muscle is a special muscle to work as a sling between rectum and anal canal. It extends from both sides of pubic bones to go posteriorly to wind the junction between rectum and anal canal. Its function is to create a anorectal angle, which by itself is a major part of the continence mechanism. Pelvic floor muscles and puborectalis sling are supplied by somatic nervous system; therefore, we can voluntary contract and relax them.

The dynamics of defecation involve both voluntary and involuntary nervous systems. Cerebral cortex first to perceive the need to evacuate rectum by sensing rectal distension. The rectal threshold volume depends on the content and rectal sensitivity. Then we will choose a correct place, time and position to defecate. The rectal content will provoke a reflex relaxation of anal sphincters and puborectalis. With Valsalva manoeuvre and relaxation of pelvic floor muscles, fecal content reaches lower rectum. It initiates a giant recto-sigmoid contraction to push the content to the relaxed anal canal. Further large propulsive rectal contractions persist until rectum is emptied. Sensory input from anus, through a reflex at spinal level, will keep this propulsive activity until rectum is fully voided. After the last bit of content passes through anal canal, the last stretch of EAS by fecal content will be followed by an exaggerated EAS contraction to prevent incontinence. That is called the closing reflex.

## Mechanism to maintain fecal continence

There are four major factors that will affect fecal continence:

◊ The plug - Anal canal acts as a plug to prevent incontinence. The haemorrhoidal cushings, IAS and EAS, as major parts of anal canal, are important to maintain continence. For example, for multiparous women or those suffered from previous birth trauma, there are injury to the sphincter complex and then it will result in incontinence. Pelvic floor muscles including puborectalis also play an important role. Particularly the puborectalis will create a angle between lower rectum and anal canal, called the anorectal angle. Too obtuse the angle will contribute to more seepage.

◊ The reservoir - Rectum acts as temporary reservoir of fecal content. If it lose the usual volume (eg after rectal resection) or normal compliance (eg after irradiation), incontinence may happen because rectum lose its buffering effect between colon and anal canal.

◊ The control - Continence is controlled through both voluntary (ie central nervous system + somatic nervous system) and involuntary (ie autonomous nervous system). Malfunction can happen at higher part such as stroke or spinal injury. It can also happen at lower level like pudendal neuropathy after birth trauma. Any damage to any part of nervous systems can result in incontinence.

◊ The content - It is easier to maintain continence against solid fecal content than loose one. Fecal content can become more solid after some medications or life style modifications.

## *Principles of surgical management of fecal incontinence*

There are several surgical intervention that we can act on the plug and the control parts.

The plug - Overlapping sphincteroplasty is the most common surgical intervention. It is best used for sphincter disruption after birth injury. Early success rate can ranges from 70 to 90 percent. However, it can only be offered to patient with reasonable remaining healthy sphincter complex and intact pudendal nerve. Effect will drop after time passes. Re-do repair is an option.

Artificial bowel sphincter (ABS) is an implant to wind around sphincters. It is best used for patients with destroyed sphincter complex or complete pudendal denervation. Since it is a foreign body, it is contraindicated for patient with chronic anal infection. The high chance of post-operative infection also leads to removal of implant for some patients.

Latest development like Injectable bulking agents (eg PTQ implant) is used to fill the defect of sphincter complex in order to improve continence function. Radiofrequency (Secca procedure) is a modality to remodel the collage fibers of anal canal so that tighter collage fibers help continence function.

The control - Sacral spinal nerves, bearing dual innervation from branches of pudendal nerves and direct branch of sacral nerves, control continence mechanism. Sacral nerve stimulation (SNS) was first used in urological incontinence. The exact mechanism is still unknown. It is postulated that SNS recruits additional function from pelvic floor musculature and pelvic organs, also affects local spinal reflex arcs to increase rectal blood flow and then reduce rectal sensory threshold. It high popularity among Western countries due to its low complication rates and high efficacy. It is contraindicated in patients with bilaterally completely damaged pudendal nerves.

Stoma can be used as last resort to divert fecel content to prevent serious buttock soiling.

## *Principles of surgical management of functional constipation*

In terms of surgical management of constipation, it can be classified as causes from pelvic outlet obstruction, from slow colonic transit or from combined.

Pelvic outlet obstruction -

1. Sigmoidocele - Serious prolapse of sigmoid colon deep into very lower part pelvis can cause constipation. Laparoscopic resection of sigmoid colon can treat the condition.

2. Rectocele - Significant anterior herniation of rectum can result in ineffective evacuation of fecal content. Repair of rectocele is indicated for symptomatic patient with non-emptying rectocele with >3cm herniation on defecating proctogram.

3. Paradoxical puborectalis syndrome - Failure to relax puborectalis will cause ineffective evacuation. Botox injection is used to relax the muscle but repeated injection may be required after effect disappears. SNS can also used to treat this condition. The exact mechanism is still unknown. It may involve direct effect on colorectal sensation and motor function or central effect on spinal cord or brain.

Slow transit constipation -

1. Total colectomy - Patients who have long colonic transit time and fails conservative management are candidates for surgical resection of colon. Though it can be done under laparoscopic means nowadays, it is still a major operation with high complication rates like adhesion, anastomotic leakage, etc.

2. Malone antegrade colonic enema (MACE) - Appendix is brought to abdominal skin and works as a conduit for insertion of catheter for antegrade colonic lavage with normal saline plus laxative. It seldom causes major complication but sometimes stoma stenosis or leakage can happen. Laparoscopic-assisted MACE is latest development in order to minimize surgical trauma.

3. Stoma - Stoma is last resort to salvage failed surgical intervention.

## *Summary*

Surgical treatment for fecal incontinence and constipation can only be considered if failed conservative management. Correct identification of pathology with corresponding investigations can guide choice of treatment and lead to satisfactory outcome. Decision making also depends on cost-effectiveness and expertise. Detailed interviews with patients and relatives are important before any surgical treatment so that patients' expectation are clearly known and risks of surgical treatment are fully explained.

**Council members:**

Ms. Chan Sau Kuen

Dr. John Fenn (Representative at FMSHK)

Dr. Cheon Willy, Cecilia

Ms. Hui Ngor, Peggy (Newsletter Editor)

Ms. Ip Kam Tin

Dr. Luk Lai Yin

Dr. Ho Kwan Lun

Ms Fung Kim Yook, Brigitte

Ms. Kwok Choi Fung, Yvonne

Ms. Tong Wai Mei, Anny

Ms. Li Wai Shan, Twinnie (Co-opt member)

**President: Dr. Leung Man Fuk**

**Vice-President: Dr. Leung Wai Yip, Michael**

Honorary Secretary: Ms. Lam Mo Ching

Honorary Treasurer: Dr. Tong Bing Chung

Webmaster: Dr. Tam Cheuk Kwan


June

貼上地址

郵票

2014

# Certificate Course in Assessment and Management of Incontinence 2014


**Dr. Cecilia Cheon**

**Consultant, Dept of O & G, QEH**



**Dr. Michael Leung**

**Consultant, Paediatric Surgeon, Dept of Surgical, QEH**

**Ms. Anny Tong**

**APN, Dept of O & G, QEH**